



Catherine Drummond

Common vulval dermatoses

Background

The vulva is skin, and it is helpful to approach vulval conditions from a dermatological perspective. The vulva is affected by the same dermatoses as the rest of the skin, but modified in appearance by special influences.

Objective

This article will outline an approach to the diagnosis and management of vulval dermatoses.

Discussion

Vulval disorders present as infections, rashes and lesions, and pain. This article considers inflammatory vulval disorders that present as erythematous rashes, pallor or erosions and ulcers. Most vulval dermatoses are recurrent or chronic and may require maintenance therapy. Chronic painful and itchy vulval conditions can lead to secondary pelvic floor spasm and a sensory neuropathy. Many vulval disorders are multifactorial and can benefit from a multidisciplinary approach to management.

Keywords: vulvar diseases; skin diseases; pruritus vulvae; vulvitis; vulvar lichen sclerosus



Vulval medicine spans dermatology, gynaecology and sexual health. Many conditions affecting the vulva are dermatological, modified by anatomical, hormonal and microbiological influences. Dermatoses that affect the vulva are the same as those that affect the rest of the skin, but the appearance is modified by the environment which produces heat, friction and occlusion. Vulval disorders present as infections, rashes, lesions and pigmentation, and pain. This article considers inflammatory vulval dermatoses that present as rashes that are erythematous, pale or erosive (*Table 1*).

Assessment

History

Ask the patient about the duration of symptoms and possible triggers at the time of onset. Is the itching constant or is there premenstrual exacerbation? Are symptoms felt 'outside' on the skin or 'inside' the vagina and associated with entry dyspareunia?

What treatments have been used and have these led to improvement or worsening of symptoms? Have antibiotics caused aggravation of symptoms? Is hormonal contraception or replacement therapy used?

A personal or family history of skin disorders, especially eczema or psoriasis is relevant, as is diabetes or autoimmune thyroid disease.

Examination

Conduct a general skin examination. There may be evidence of facial, hand or flexural dermatitis. Erythema and scale on the scalp, pitting of nails and onycholysis, thickening of the extensor aspect of elbows and knees suggests psoriasis.

Examine the vulval and perianal skin. If erythema is noted, is it diffuse or does it have a well defined border? Does it spare or extend into the folds, such as the inguinal and gluteal creases? Is there lichenification (thickening of the skin with increased skin markings) or pigmentation? Is there associated vaginitis?

If pallor is noted, what is the distribution and is there alteration in the skin texture?

Is there epithelial loss (erosions or ulcers) on the vulval skin or mucosa?



Table 1. Presentation of vulval dermatoses

Erythematous
<ul style="list-style-type: none">• Dermatitis – atopic, irritant contact, allergic contact, seborrheic, oestrogen hypersensitivity• Chronic vulvovaginal candidiasis• Psoriasis• Tinea cruris
Pallor
<ul style="list-style-type: none">• Vitiligo• Lichen sclerosus• Lichen simplex chronicus• Vulval intraepithelial neoplasia
Erosions/ulcers (noninfective)
<ul style="list-style-type: none">• Aphthous ulcers• Lichen planus• Immunobullous diseases – pemphigus vulgaris

Investigation

Take a low vaginal swab on all first presentations. If *Candida albicans* is grown it may be relevant to the diagnosis. However, a positive swab is not diagnostic as candida may be a commensal. The swab may be negative if antifungal therapy has been used recently. If a swab grows non-albicans *Candida* these may not be pathogenic.

Biopsy of vulval skin or mucosa may assist in diagnosis. Biopsy from this area of the skin is no different technically from anywhere else, but it can be more distressing and painful to the patient. Topical anaesthetic applied before anaesthetic injection may help reduce pain. The most appropriate type of biopsy is a punch biopsy of 3–4 mm diameter. Haemostasis may be obtained either with silver nitrate or an absorbable suture. This procedure can be performed by a general practitioner competent in skin biopsy.

General principles of management

Management of all vulval dermatoses involves environmental modification. Advise the patient to use a nonsoap cleanser and to wear loose cotton clothing. Vulval irritants (Table 2) should be minimised.

Topical corticosteroids (Table 3) are the mainstay of treatment for inflammatory vulval disorders. Ointments are better tolerated than creams as they are less likely to cause stinging. Use a potent corticosteroid for more rapid and effective control, tapering to a weak agent. Atrophy is rare with short term use of potent corticosteroids.

Prognosis

Most of these vulval conditions are chronic, and women need to be educated to expect that ongoing treatment is often necessary.

Differential diagnoses

Erythema

If poorly defined erythema is noted, the most likely diagnosis is dermatitis (eczema). Lichenification and hyperpigmentation occurs

Table 2. Vulval irritants

- Soap, water, detergents
- Vaginal discharge, urinary and faecal incontinence
- Hair removal
- Fragrances, douches
- Lubricants, condoms
- Sanitary pads, panty liners
- G-strings, tight jeans, gym clothing
- Cycling, horse riding, gym exercise
- Swimming, saunas, spas

Table 3. Corticosteroid ointments for vulval use

Ultrapotent

- Betamethasone dipropionate in optimised vehicle 0.05

Potent

- Betamethasone dipropionate 0.05%
- Methylprednisolone aceponate 0.1%

Weak

- Hydrocortisone 1%

when dermatitis is chronic, and this is referred to as 'lichen simplex chronicus' (Figure 1).

If there is vulval dermatitis, with premenstrual exacerbation of itch, worsening with antibiotics, and partial improvement with antifungal therapy, consider chronic vulvovaginal candidiasis (Figure 2). There is usually associated vaginitis and a scanty adherent white discharge may be noted, and sometimes satellite papules and pustules on the adjacent skin.

In psoriasis (Figure 3), erythema has a better defined border with involvement of the folds and extension into the gluteal crease. Scale is often absent because of the moist environment. There is no vaginitis. Seborrheic dermatitis overlaps with psoriasis.

In tinea cruris (Figure 4) there is central clearing, sparing of creases, peripheral scaling and follicular papules. Examine the feet for tinea pedis. If tinea is suspected, take scrapings and send for fungal microscopy and culture.

Biopsy may not be diagnostic for erythematous vulval rashes. Histopathology will not distinguish between various types of dermatitis and will not exclude candidiasis. Classic histopathological features of psoriasis may not be evident. A biopsy may be indicated where there is a treatment resistant erythematous rash.

Most cases of vulval dermatitis are atopic. There is usually a personal and/or family history of eczema, asthma or hayfever, with a genetic predisposition to an impaired epidermal barrier – which is more easily irritated – so there is usually a superimposed irritant contact dermatitis.

Treat with a potent topical corticosteroid ointment until symptoms resolve – 2–3 weeks is usually sufficient – then taper to hydrocortisone 1% ointment daily for another 2–3 weeks to prevent a flare.¹ For recurrences after the initial treatment phase, short term



potent topical corticosteroid ointment can be used.

If corticosteroids do not control symptoms or are required continuously, consider other causes of dermatitis including chronic candidiasis or oestrogen/progesterone hypersensitivity dermatitis. If allergic contact dermatitis is suspected, refer to a dermatologist for patch testing.

Extramammary Paget disease presents as itchy eczematous plaques that may be eroded and weeping and resistant to topical corticosteroid therapy. Biopsy will be diagnostic. Investigation is then indicated to exclude presence of local or distant adenocarcinoma of the lower gastrointestinal, urinary and genital tracts. The patient should be referred to a gynaecological oncologist.

Chronic vulvovaginal candidiasis is thought to be an innate hypersensitivity reaction to *Candida* rather than an infection.² It commonly affects women aged 20–40 years who are immunocompetent. Oestrogen seems to be a localising cofactor and therefore the diagnosis of vulvovaginal candidiasis is highly unlikely in prepubertal girls. It is uncommon in postmenopausal women who are not on hormone therapy unless there are predisposing factors such as diabetes or immunosuppression.

Approach to management involves suppression of *Candida* and treatment of the associated dermatitis. Hydrocortisone 1% ointment can be used for symptomatic control of itch. Both topical and oral antifungal azoles are equally effective. Fluconazole can be prescribed at 150 mg every 3 days for 2 weeks, then maintenance treatment 150

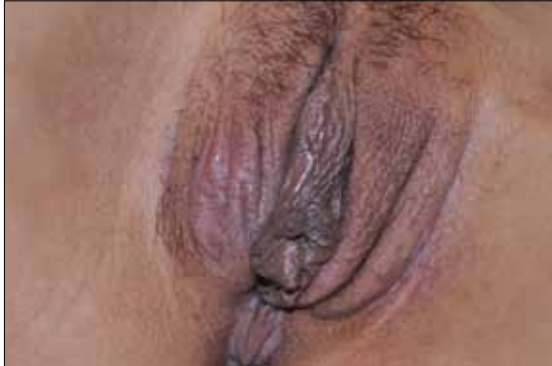

Figure 1. Lichenified dermatitis

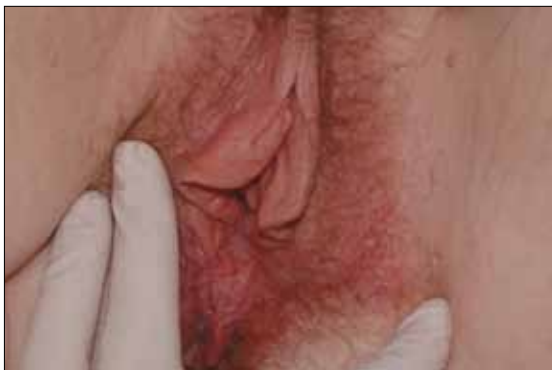

Figure 2. Candidiasis

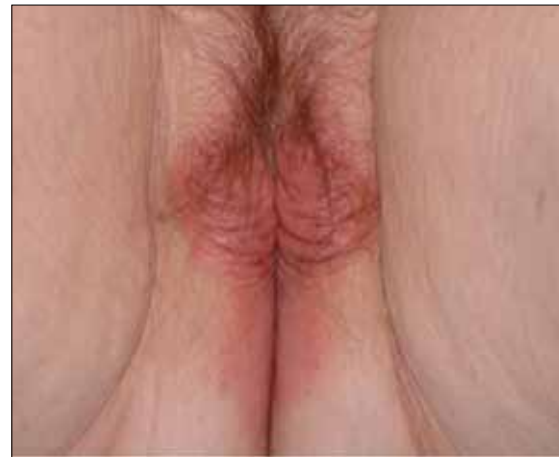

Figure 3. Psoriasis

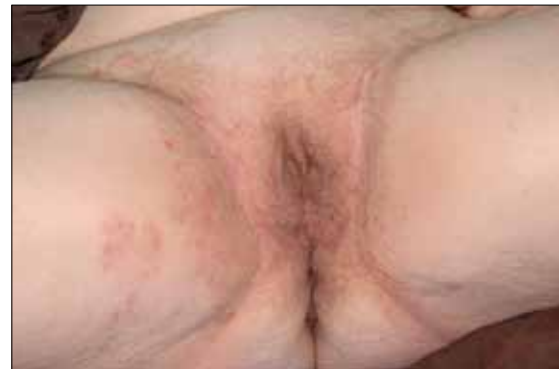

Figure 4. Tinea cruris

mg weekly for 6 months;³ or alternatively 50 mg/day until symptoms improve then slow withdrawal over 3–6 months. Fluconazole is less hepatotoxic than ketoconazole and itraconazole. Check for drug interactions and contraception. Creams used long term are irritating, so if topical therapy is chosen, vaginal pessaries should be used: clotrimazole pessaries 100 mg/day until resolution of clinical signs and symptoms then 500 mg weekly for 6 months.

Fifty percent of women experience recurrence after cessation of treatment, necessitating maintenance treatment varying from daily to monthly dosing. If non-albicans *Candida* is thought to be the cause of symptoms, imidazole antifungals are less effective. Boric acid pessaries 600 mg can be prescribed.⁴

Oestrogen and progesterone hypersensitivity dermatitis are rare disorders which should be considered if there is dermatitis refractory to treatment with topical corticosteroids, with cyclical premenstrual exacerbation where low vaginal swabs are consistently negative for *Candida* and there is no response to antifungal agents. Definitive diagnosis is made by intradermal testing, however this is only available in a research setting, therefore diagnosis involves suspicion and exclusion of other diagnoses. Treatment consists of cycle suppression, which is most appropriately supervised by a gynaecologist.⁵

Initial management of psoriasis is similar to that of dermatitis:



a potent topical corticosteroid ointment for a few weeks. Psoriasis usually takes longer to resolve and is more likely to require ongoing maintenance treatment than dermatitis. Weak tars such as LPC 2% in aqueous cream or calcipotriene ointment can be used as steroid sparing agents. Recurrence can be managed with a potent topical corticosteroid ointment. If psoriasis is part of severe widespread disease, consider referral to a dermatologist for systemic therapy.⁶

Tinea is managed with a topical antifungal cream, either terbinafine or an imidazole. If there is follicular involvement or lack of response to therapy, an oral antifungal is indicated, either griseofulvin 500 mg/day or terbinafine 250 mg/day until resolution. Treat tinea pedis to prevent recurrence.⁶

Pallor

Diagnoses to consider are: lichen sclerosus, vitiligo, lichen simplex chronicus, and vulval intraepithelial neoplasia (VIN).

Vitiligo is asymptomatic and produces depigmentation (accentuated by a Wood lamp), with no alteration of epidermal texture. It can be difficult to distinguish from lichen sclerosus. Biopsy requesting melanocyte stains can be helpful as melanocytes are absent in vitiligo. Treatment is only indicated for cosmetic reasons; potent corticosteroid ointments are used first line.

In lichen sclerosus (*Figure 5*) there are porcelain white papules, coalescing into plaques that may be atrophic or hyperkeratotic. There may be fissures or purpura. If extensive, it may have a 'figure of 8' distribution around the vulva and anus. It does not involve the mucosa. In later stages, alteration of vulval architecture occurs (*Figure 6*), with obliteration of clitoral hood, resorption of labia minora, labial adhesions and introital stenosis. A biopsy is usually indicated to confirm lichen sclerosus (*Figure 7*) as it is a chronic condition with a risk of scarring and malignancy. Diagnosis is made clinically in prepubertal girls.

Lichen sclerosus is thought to be an autoimmune condition with a genetic basis. There is often a personal or family history of autoimmune



Figure 5. Early lichen sclerosus

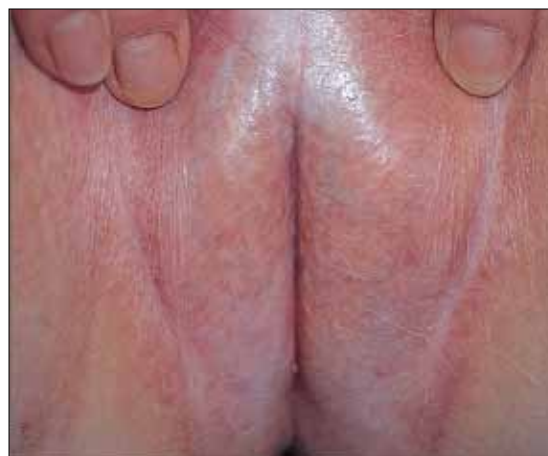

Figure 6. Late lichen sclerosus

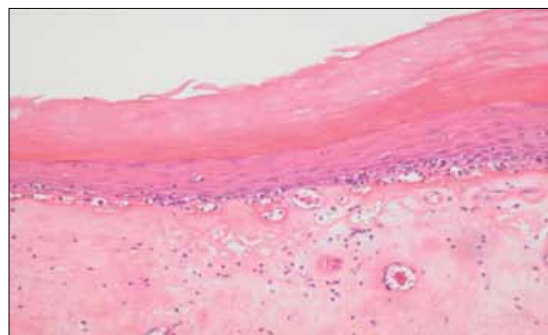


Figure 7. Histopathology of lichen sclerosus

disease, especially thyroid disease. If not already diagnosed, checking thyroid antibodies and thyroid stimulating hormone is worthwhile.

Although usually itchy, lichen sclerosus may be asymptomatic, and incidentally noted when a woman presents for a screening Pap test. Lichen sclerosus usually needs treatment for symptom relief, and for prevention or limitation of scarring and architectural distortion. Although there is no published evidence, suppression of inflammation may reduce the risk of squamous cell carcinoma from 5–6%.⁷

After a biopsy, commence an ultrapotent corticosteroid ointment twice daily until symptoms resolve,⁸ then use daily. Use a potent corticosteroid ointment initially in prepubertal girls. Usually symptomatic improvement is rapid but this treatment should be continued daily until review after 8–12 weeks. If the appearance has normalised, reduce potency of the topical corticosteroid with the aim of maintenance treatment with hydrocortisone 1% ointment daily,⁹ with the addition of a stronger preparation for flares. Topical calcineurin inhibitors (eg. pimecrolimus or tacrolimus) are not recommended as it is thought they may increase the risk of squamous cell carcinoma.¹⁰

If lichen sclerosus presents in prepubertal girls, it is now accepted that lichen sclerosus does not resolve at puberty.¹¹ Women and girls with lichen sclerosus require ongoing follow up, usually every 6 months to check for progression of scarring, and for any areas suspicious for squamous cell carcinoma: persistent hyperkeratosis, erythema or ulceration.



Vulval intraepithelial neoplasia represents in situ squamous cell carcinoma and is equivalent to Bowen disease of sun exposed skin. In younger women it is associated with oncogenic types of human papilloma virus and referred to as 'usual VIN'. In older women it usually arises within lichen sclerosus and termed 'differentiated VIN'.¹² It may present as a localised, pale rough plaque but the appearance is highly variable: solitary or multiple, papules or plaques which may be erythematous or pigmented. Suspect VIN and perform a biopsy for any persistent area of abnormality that is thick, warty or ulcerated. Refer to a gynaecological oncologist for further management.

Erosions

Women usually present with pain due to epithelial breach. The commonest cause of vulvovaginal erosions and ulcers, once herpes simplex virus (HSV) infection has been excluded, is aphthous ulceration (*Figure 8*). This may be idiopathic or secondary to viral infections (Epstein Barr virus or cytomegalovirus), and autoimmune conditions such as Behçet disease, Crohn disease and lupus erythematosus. Usually the only investigation needed is a viral swab for HSV.

Biopsy of an aphthous ulcer is nondiagnostic, but may be useful to exclude other conditions such as Crohn disease (granulomatous inflammation) or immunobullous diseases such as pemphigus vulgaris (with direct immunofluorescence). Further investigation for autoimmune diseases may be considered if clinically indicated.

Management of idiopathic aphthous ulcers includes general measures such as saline cleansing and pain relief. Apply an ultrapotent topical corticosteroid every 2–4 hours at the ulcer onset. If severe, oral prednisolone can be used: 25 mg/day until ulcers heal, then 12.5 mg/day for 2–3 weeks. Doxycycline may be useful for the management of recurrent aphthous ulcers.¹³

Lichen planus (*Figure 9*) presents as painful vaginal mucosal erosions. A grey border can be a clue, and there may be cutaneous involvement with a violaceous erythematous rash on the vulval skin associated with Wickham striae. There may be associated oral mucosal involvement. Biopsy of cutaneous lichen planus is characteristic, but erosive mucosal lesions may be nonspecific.

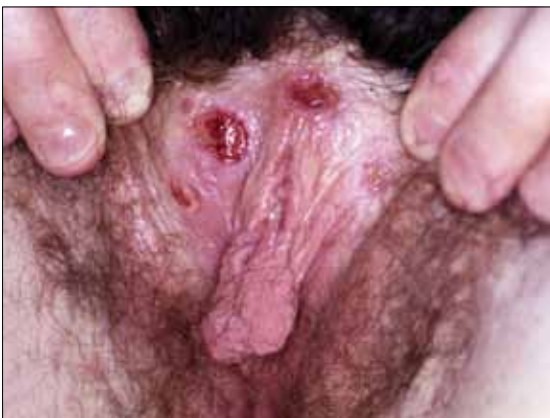

Figure 8. Aphthous ulceration

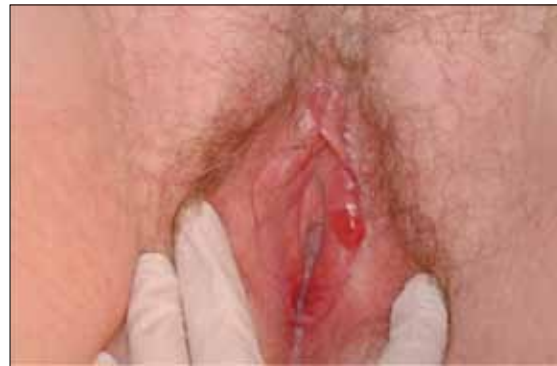

Figure 9. Lichen planus

Lichen planus may be a recalcitrant condition to treat and usually requires specialist referral. Management options include ultrapotent topical corticosteroid ointment, oral prednisolone, and if more severe, systemic treatment with hydroxychloroquine, acitretin or methotrexate.¹⁴

Desquamative inflammatory vaginitis¹⁵ can be difficult to distinguish from lichen planus. Symptoms are pain, discharge and superficial dyspareunia. Examination shows erythematous patches without loss of epithelial integrity. It is a noninfectious vaginitis, perhaps due to altered vaginal homeostasis, and may be synonymous with Zoon or plasma cell vulvitis. Low vaginal swabs report mixed vaginal flora, increased polymorphs and epithelial cells. Biopsy is nondiagnostic and shows a mixed inflammatory infiltrate, which may be lichenoid and includes plasma cells. This condition usually responds promptly to a topical anti-inflammatory antibiotic applied daily until symptoms resolve.¹⁶ Useful agents include clindamycin 2% cream, mupirocin 2% ointment or metronidazole 0.75% gel. Hydrocortisone 1% ointment or 10% foam can be used if required. Relapse is common and maintenance treatment twice weekly may be necessary.

Other issues

Any vulval dermatosis that is persistently itchy or painful may result in secondary pelvic floor spasm or a sensory neuropathy (vulvodynia). Consider referral to a physiotherapist specialising in the pelvic floor. If persistent and severe, neuropathic pain may require treatment with drugs such as amitriptyline, gabapentin or pregabalin.

Chronic vulval dermatoses may cause considerable distress and referral for counselling, or to a support group, may benefit some women. Patient information is available at www.caredownthere.com.au.

Summary

This article has discussed inflammatory vulval disorders that present as erythematous rashes, pallor or erosions and ulcers. Most vulval dermatoses are recurrent or chronic and may require maintenance therapy. Chronic painful and itchy vulval conditions can lead to secondary pelvic floor spasm and a sensory neuropathy. Many vulval disorders are multifactorial and can benefit from a multidisciplinary approach to management.



Further reading

Fisher G, Bradford J. The vulva: a clinician's practical handbook. Family Planning NSW, 2010.

Author

Catherine Drummond MBBS(Hons), DCCH(Edin), FRACGP, FACD,
Department of Dermatology, Canberra Hospital, Australian Capital
Territory. drcatherinedrummond@gmail.com.

Conflict of interest: none declared.

References

1. Fischer G. Treatment of vaginitis and vulvitis. *Aust Prescr* 2001;24:59–61.
2. Fidel PL Jr. History and update on host defense against vaginal candidiasis. *Am J Reprod Immunol* 2007;57:2–12.
3. Sobel JD, Wiesenfeld HC, Martens M, et al. Maintenance fluconazole therapy for recurrent vulvovaginal candidiasis. *N Engl J Med* 2004;351:876–83.
4. Ray D, Goswami R, Banerjee U, et al. Prevalence of *Candida glabrata* and its response to boric acid vaginal suppositories in comparison with oral fluconazole in patients with diabetes and vulvovaginal candidiasis. *Diabetes Care* 2007;30:312–7.
5. Fischer GO, Ayer B, Frankum B, Spurett B. Vulvitis attributed to estrogen hypersensitivity: report of 11 cases. *J Reprod Med* 2000;45:493–7.
6. Genital skin diseases. Therapeutic Guidelines: dermatology. Version 3. North Melbourne: Therapeutic Guidelines 2009;131–45.
7. Jones RW, Sadler L, Grant S, Whineray J, Exeter M, Rowan D. Clinically identifying women with vulvar lichen sclerosus at increased risk of squamous cell carcinoma: a case-control study. *J Reprod Med* 2004;49:808–11.
8. Dalziel KL, Millard PR, Wojnarowska F. The treatment of vulval lichen sclerosus with a very potent topical steroid (clobetasol propionate 0.05%) cream. *Br J Dermatol* 1991;124:461–4.
9. Bradford J, Fischer G. Long-term management of vulval lichen sclerosus in adult women. *Aust N Z J Obstet Gynaecol* 2010;50:148–52.
10. Fischer G, Bradford J. Topical immunosuppressants, genital lichen sclerosus and the risk of squamous cell carcinoma: a case report. *J Reprod Med* 2007;52:329–31.
11. Smith SD, Fischer G. Childhood onset vulvar lichen sclerosus does not resolve at puberty: a prospective case series. *Pediatr Dermatol* 2009;26:725–9.
12. Heller D. Report of a new ISSVD classification of VIN. *J Low Genit Tract Dis* 2007;11:46–7.
13. Preshaw PM, Grainger P, Bradshaw MH, Mohammad AR, Powala CV, Nolan A. Subantimicrobial dose doxycycline in the treatment of recurrent oral aphthous ulceration: a pilot study. *J Oral Pathol Med* 2007;36:236–40.
14. Jang N, Fischer G. Treatment of erosive vulvovaginal lichen planus with methotrexate. *Australas J Dermatol* 2008;49:216–9.
15. Sobel JD. Desquamative inflammatory vaginitis: a new subgroup of purulent vaginitis responsive to topical 2% clindamycin therapy. *Am J Obstet Gynecol* 1994;171:1215–20.
16. Sobel JD, Reichman O, Misra D, Yoo W. Prognosis and treatment of desquamative inflammatory vaginitis. *Obstet Gynecol* 2011;117:850–5.

correspondence afp@racgp.org.au